

Esophageal Spasm

The ***2*** forms of spastic disorders,

1. **d*iffuse* e*sophageal***

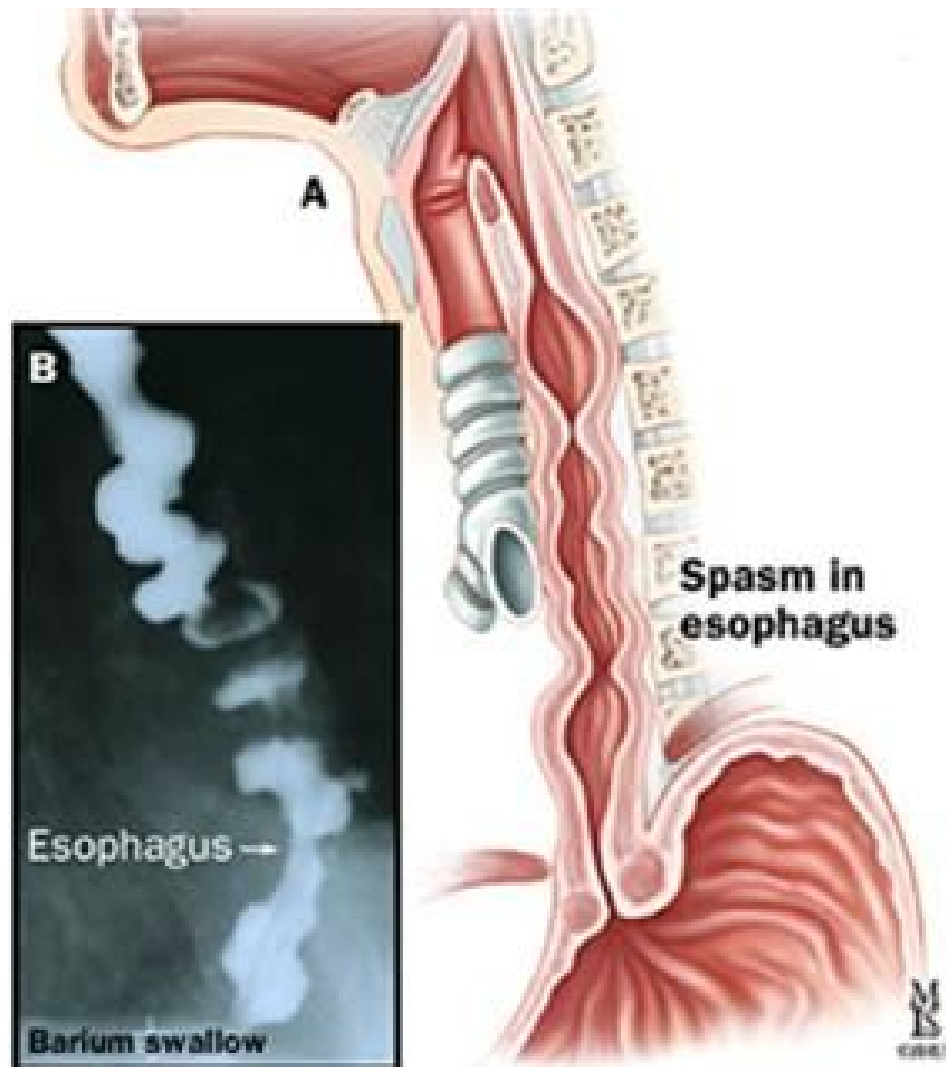
s*pasm* (DES) and

2. **nu*tracker* esophagus,**

are clinically

in*distinguishable*.

Esophageal Spasm



Esophageal Spasm

Both (**D*****ES*** and
nu***tracker***) present
with the **sudden** **onset**
of ***chest*** ***pain*** that is
not related to ***exertion***.



Esophageal Spasm

Therefore, at **first** it is

impossible to

distinguish them from

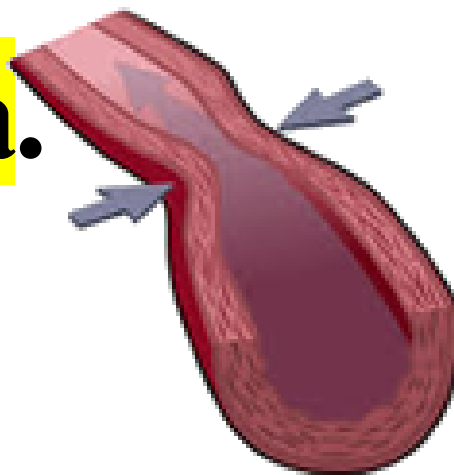
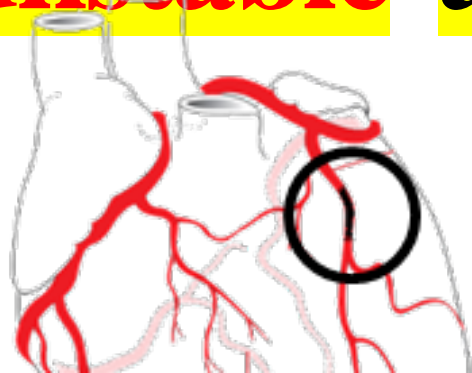some form of **atypical**

***coronary* *artery* spasm**

or

**PRINZMETAL ANGINA
ARTERY SPASM**

***unstable* angina.**



Esophageal Spasm

They can

be precipitated by

drinking *cold* *liquids*



Esophageal Spasm

The case will describe

sudden, severe *chest*

pain and the *EKG*

and *stress* test will be

normal.

Esophageal Spasm

Eso*phagram* and

End*oscopy* will be

normal.

Esophageal Spasm

DES and **nutcracker**

esophagus can be

distinguished only by the

most accurate test -

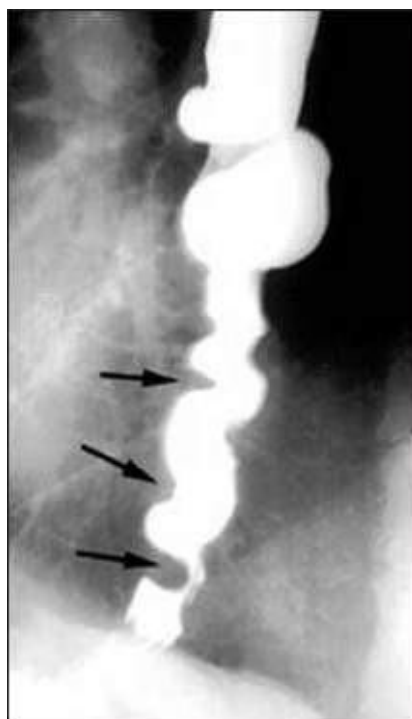
manometry, which will

show a **different pattern**

of **ab*normal* con*traction***

in each of them.

Esophageal Spasm



Esophageal Spasm

Figure 1.3 - ***Barium***

studies can show a

cor***kscrew** ***appearance**

at the time of the **spasm.**

Esophageal Spasm

Esophageal spastic

disorders are treated

with

calcium* *channel

blockers and nitrates*•

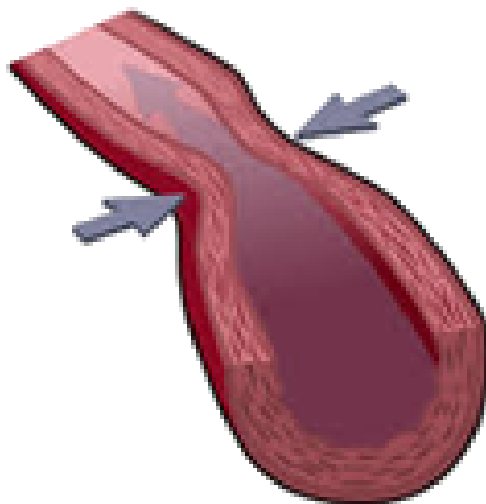
Esophageal Spasm

This is **similar** to the

treatment of

***Prinzmetal* *angina*•**

**PRINZMETAL ANGINA
ARTERY SPASM**



Esophageal Spasm

***PPI**s* can



improve a number

of **cases** of **spastic**

disease.

Esophageal Spasm

Tricyclic



antidepressants can be

used **instead** of

calcium channel

blockers.



Ca Channel Blockers



Esophageal Spasm

Sildenafil is an

alternative if these

fail.

